



PATIENT

Nutmeg Rettie

SPECIES

Feline

BREED

DSH

SEX

Male Neutered

AGE

14 years

WEIGHT

10.7lbs

INTERPRETED BY

Maggie Machen Lamy,
DVM DACVIM
(Cardiology)

IMAGING PERFORMED BY

Kelly Reschny, RVT

HOSPITAL NAME

East Credit Veterinary
Hospital

REFERRING VET

Dr. Webster

INVOICE

28244

DATE

1/11/23

PRESENTING CLINICAL SIGNS

History: History of seizures. Presented as new patient with tachycardia, abd effort resp, gallop rhythm with arrhythmia, pleural effusion on radiographs. Started furosemide, recheck radiographs today. Owner's report doing well over weekend, calmer breathing. Chest radiographs showed significant improvement, less effusions, cardiac silhouette now partially visible
-Current medications: Gabapentin, Furosemide 10mg TID.

ECHOCARDIOGRAM FINDINGS

2D, m-mode, color flow and doppler imaging is available. Mild left ventricular dilation with diminished systolic function. The LV wall thickness is asymmetric, with mild septal thickening and a region of thinning. Marked left atrial enlargement with subtle smoke seen. The mitral valve appears normal in form and function, with no obvious prolapse into the left atrial lumen. Mild central mitral regurgitation. The tricuspid valve appears normal in form and function. Severe right atrial dilation. Trace tricuspid regurgitation. The aortic valve is normal in morphology and mobility. Decreased LVOT and RVOT velocities. No aortic or pulmonic insufficiency. Scant pericardial effusion noted. Pockets of pleural effusion noted. No obvious cardiac tumors. Irregular tachycardia throughout.

CARDIAC CHART

FELINE CARDIAC PARAMETERS	BODY WEIGHT (kg)	HR (BPM)	IVSd (cm) (Moise, Pipers)	LVIDd (cm) (Moise, Pipers)	LVWd (cm) (Moise, Pipers)	FS (%)	EF (%)
NORMAL PARAMETER	-----	150-240	0.35-0.55	<2 (mean 1.5)	3.5-0.55	35-67	80-100
PATIENT	4.87	250	0.47	1.9	0.46	16	30
FELINE CARDIAC PARAMETERS	LA/AO (Boon)	LA/AO HEART BASE (Swe) (Abbott)	LA 2D short axis Base view (cm) (Abbott)		LVOT VEL (m/s)	RVOT VEL (m/s)	E max (m/s)
NORMAL	<1.5	<1.3	<1.2		<1.6	<1.3	<0.9
PATIENT	2.5	2.6	2.4		0.6	0.3	NM
<p><i>*Note: All measurements based upon multi-modal images and methods. An average value is reported.</i> Adapted from June Boon, Veterinary Echocardiography, 1998 Abbott J & MacLean H JVIM 2006;20: 111-119, Moise et al. Am J Vet Res 47:1476, 1986. Pipers et al. Am J Vet Res 40:882, 1979.</p>							

INTERPRETATION OF THE FINDINGS & FURTHER RECOMMENDATIONS

Unfortunately, this patient has end-stage cardiomyopathy and biventricular systolic dysfunction. This is causing dilation and overload of all 4 chambers, resulting in insufficiency of the AV valves. The degree of dilation and pump failure is resulting in suspected congestive heart failure based upon reported labored breathing and persistent effusion. Irregular tachycardia is noted throughout the study, and a baseline ECG is strongly recommended.

In cats, systolic failure can be primary in nature (DCM); however, this is relatively uncommon. An advanced form of restrictive cardiomyopathy (RCM) with development of systolic dysfunction is also possible. Finally, systolic failure can develop secondary to



PATIENT

Nutmeg Rettie

taurine deficiency, myocarditis, or infiltrative disease such as lymphoma. Taurine deficiency is highly uncommon in cats on commercially prepared cat foods; however, can consider taurine supplementation in case of an absorption issue.

SPECIES

Feline

These findings support the diagnosis of congestive heart failure and continued lifelong cardiac support is recommended as below. If medicating the patient is difficult at home, consider liquid Lasix and/or compounding the medications into a liquid or alternative option. Prognosis is poor to grave at this stage in the disease process, with an average survival time of <6 months. Most cats are able to maintain a good QOL for some time however on oral medication. High risk for recurrent CHF, development of blood clot events and/or malignant arrhythmias/sudden death at home should be discussed.

BREED

DSH

SEX

Male Neutered

Monitor for development of labored breathing, limb paralysis/neurologic changes and/or collapse episodes in the future. Periodic Thoracocentesis will be necessary going forward. Monitoring of sleeping breathing rates at home is recommended to assess response to medications and recurrence of CHF in the future.

AGE

14 years

PLAN

Baseline ECG recommended. Consider hospitalization for stabilization. Administer Lasix/furosemide 1-2mg/kg PO q12h. Institute anti-coagulant Plavix/Clopidogrel 75mg tabs; Give ¼ tab by mouth every 24 hours (NOTE: bitter along cut edge, may cause foaming at the mouth; coat in entirety). Institute heart muscle support Pimobendan 1.25mg by mouth every 12 hours (off label use). Consider supplement taurine 500mg daily.

WEIGHT

10.7lbs

INTERPRETED BY

Maggie Machen Lamy,
DVM DACVIM
(Cardiology)

Recheck renal panel and BP in 1-2 weeks then every 3-4 months lifelong. Do not utilize an ACEI in this patient. If patient continues to have respiratory changes at home, addition of spironolactone is recommended 1-2mg/kg PO q12h.

IMAGING PERFORMED BY

Kelly Reschny, RVT

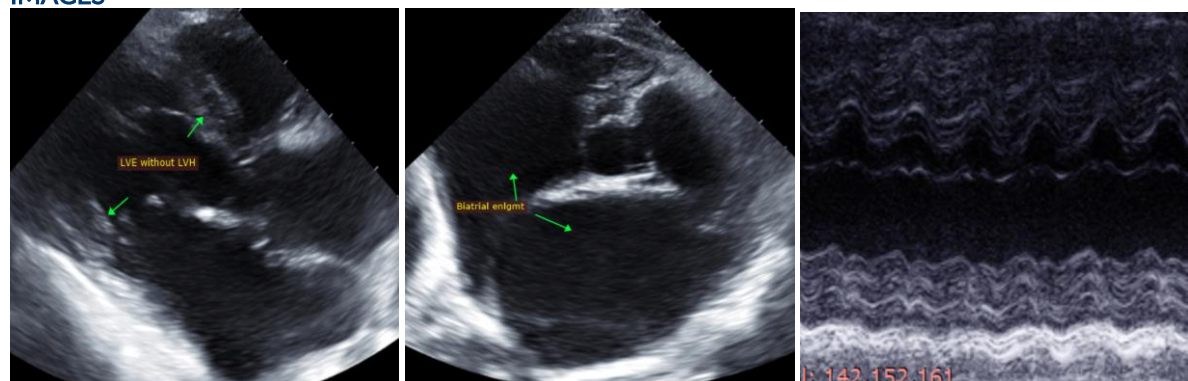
*NOTE: Many cats are difficult to medicate, and multiple medications can be overwhelming. If there is difficulty at home, Lasix and Plavix are considered most important. Consider compounding if needed.

Recheck echocardiogram in 6 months to reassess cardiac function.

HOSPITAL NAME

East Credit Veterinary
Hospital

IMAGES



REFERRING VET

Dr. Webster

INVOICE

28244

DATE

1/11/23



PATIENT

Nutmeg Rettie

The information and recommendations provided are based on the images presented by the referring veterinarian. No evaluation can be communicated regarding pathology that was not visible in the image/video clips provided.

SPECIES

Feline

Thank you for this referral. This report was generated using transcription software, and minor dictation errors may be present. If the clinical or image interpretation does not parallel your findings or if I can be of any further assistance, please contact me.

BREED

DSH

Maggie Machen Lamy, DVM
Diplomate of the American College of Veterinary Internal Medicine (Cardiology)
info@sonopath.com

SEX

Male Neutered

AGE

14 years

WEIGHT

10.7lbs

INTERPRETED BY

Maggie Machen Lamy,
DVM DACVIM
(Cardiology)

**IMAGING
PERFORMED BY**

Kelly Reschny, RVT

HOSPITAL NAME

East Credit Veterinary
Hospital

REFERRING VET

Dr. Webster

INVOICE

28244

DATE

1/11/23